

One Puff Too Many

Crystal Bauman, MD and Laura Kolster, DO

History & Physical

23 year old previously health male presents with shortness of breath and chest pain. He also reports 4 days of congestion and cough. During a cough fit this morning he suddenly developed pain in his left upper chest and back. No fevers, leg swelling, travel. He is a current daily smoker of tobacco and marijuana and uses electronic cigarettes regularly. He works as a pool service technician.

Vitals: Temp: 37C (oral), BP:105/80, HR:124, RR: 18, O2: 90% RA

General: Lying on stretcher in no acute distress.

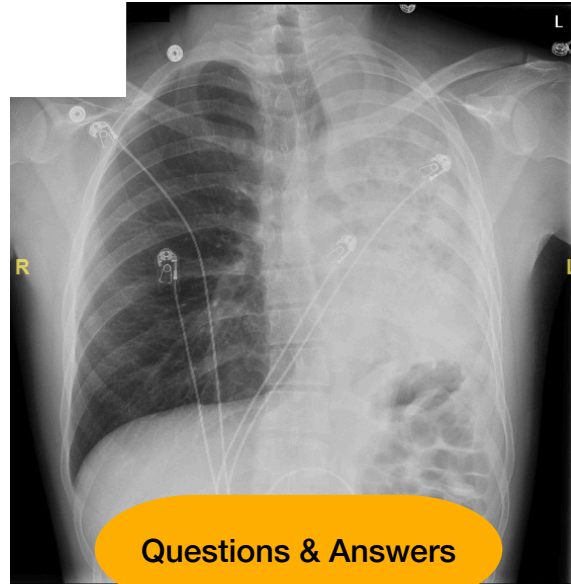
Respiratory: Normal effort. Decreased breath sounds on entire left side with faint crackles. No wheezing.

Cardiac: Tachycardic. Regular rhythm. No murmurs.

Musculoskeletal: No spinal or muscular tenderness to palpation of back. No deformities. No lower extremity swelling or tenderness bilaterally.

Labs

WBC 17. Hgb 13.
CMP unremarkable
Troponin negative
RVP negative



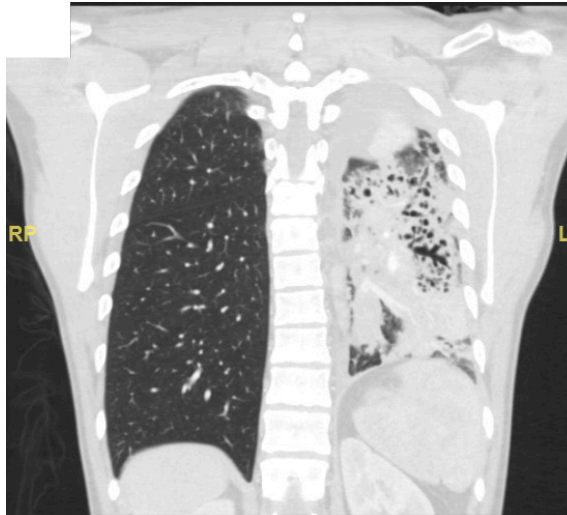
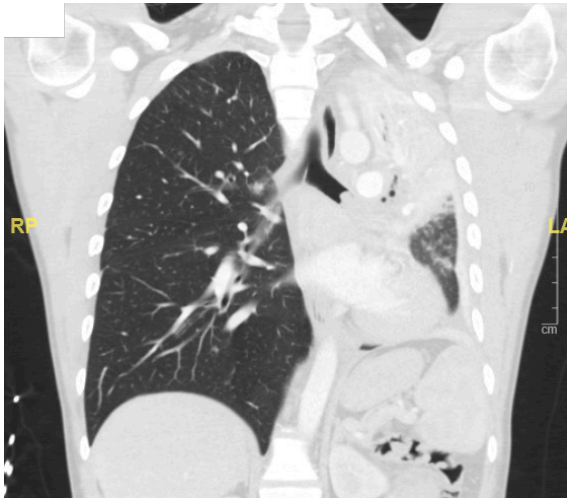Questions & Answers

1. What are differentials for complete opacification of a hemithorax?

The differentials include atelectasis, pneumonectomy, consolidation, ARDS, pleural effusion, and/or mass.

2. What clue does the CXR show that leads you towards a diagnosis?

Given that the trachea is deviated to the affected side, it makes the diagnosis more consistent with total lung collapse.



Discussion

Patient presented similarly to the ED 4 months prior. At that time he was found to have a retrocardiac mass on CXR. This was further evaluated with a contrast-enhanced chest CT showing complete consolidation of the LLL secondary to an endobronchial obstruction. Patient had rigid bronchoscopy by cardiothoracic surgery during which they successfully removed a foreign body blocking the LLL bronchus, thought to be a mucus plug. Respiratory cultures grew *Staphylococcus aureus*. He was discharged the following day on PO antibiotics. On the second presentation, his CXR shows complete opacification of the left hemithorax confirmed with CT to represent near total left lung atelectasis. Patient had a repeat bronchoscopy which showed purulent material completely occluding the left main bronchus. Cultures again grew MSSA and he was treated appropriately with antibiotics. Patient was evaluated by pulmonology who felt that his recurrent atelectasis and infection was secondary to tobacco and marijuana use. Patient was counseled on smoking/vaping cessation and discharged after an uncomplicated hospital course.

Pearls

- In otherwise healthy and young patients it is especially important to ask about social habits such as smoking or vaping.
- A recent study by the CDC showed that from 2011 to 2019 there has been a 29% increase in teens using vaping products. As reported in February of 2020 there have been 2800 cases of lung injuries from vaping requiring hospitalization and 68 deaths. Keep a broad differential for those that vape and consider more extensive work-up.