These Are Your Lungs On Drugs: Dyspnea And Intravenous Drug Abuse

Hugh M. Hiller MD, CPT, MC, USA[2]; David S. Marsh, MD[1];
Shekhar A. Ghamande, MD, FCCP, FAASM[1]; Joel Miller, MD,FAAEM[2]; Drew Jeurgens, MD[1]

Baylor Scott & White Medical Center, Temple, TX[1]; Carl R. Darnall Army Medical Center, Fort Hood, TX[2]

History

HPI: A 27-year-old presents to the Emergency Department (ED) complaining of seizure like activity lasting several minutes and shortness of breath. He is back to baseline and denies any recent illicit drug use, but states he has not been taking any of his prescribed medications including his anticoagulation. He has an extensive recent hospitalization history, including a hospitalization three months prior for cardiopulmonary arrest, presumably secondary to hypoxia from a massive pulmonary embolus (PE). During his recent hospital stay for his PE there were multiple nursing concerns that the patient was not taking his oral narcotics and saving them to take at once to "get high".

PM/S/FHx: Polysubstance abuse including IV and oral narcotics, chronic pulmonary embolism, Chron's disease, medication noncompliance.

Physical Exam

Vitals: BP: 133/84, Pulse: 97, RR: 24, SpO2: 98% on room air, Temperature 98.5 oral
General: Mild distress, no conversational dyspnea, speaking full sentences
Respiratory: Significant inspiratory and expiratory rales bilaterally. Moderate respiratory distress.
Cardiovascular: Regular rate and rhythm, no murmurs, gallops, or rubs
Abdomen: soft, non-tender, non-distended
Neuro: Normal sensation and strength (5/5) in all extremities. Gait normal.
Extremities: No cyanosis, clubbing, or edema. Multiple needle track marks in b/l antecubital fossae

Questions

1. What is the significance of this patient's respiratory distress in light of his forearm track marks and abuse of oral narcotics?

2. What is the ultimate diagnosis, and why is a large portion of the left lung seemingly spared from the otherwise disseminated disease process?

Disclaimer

The views expressed herein are those of the authors and do not reflect the official policy or position of the Department of the Army, Department of Defense, or the US Government. The authors are employees of the US government. This work was prepared as part of their official duties and, as such, there is no copyright to be transferred.

Figure I: Coronal view of a CT Chest Angiogram with IV contrast demonstrating diffuse ground glass infiltrates sparing the portion of left lung that is infarcted. This is consistent with pulmonary talcosis via the intravenous route.

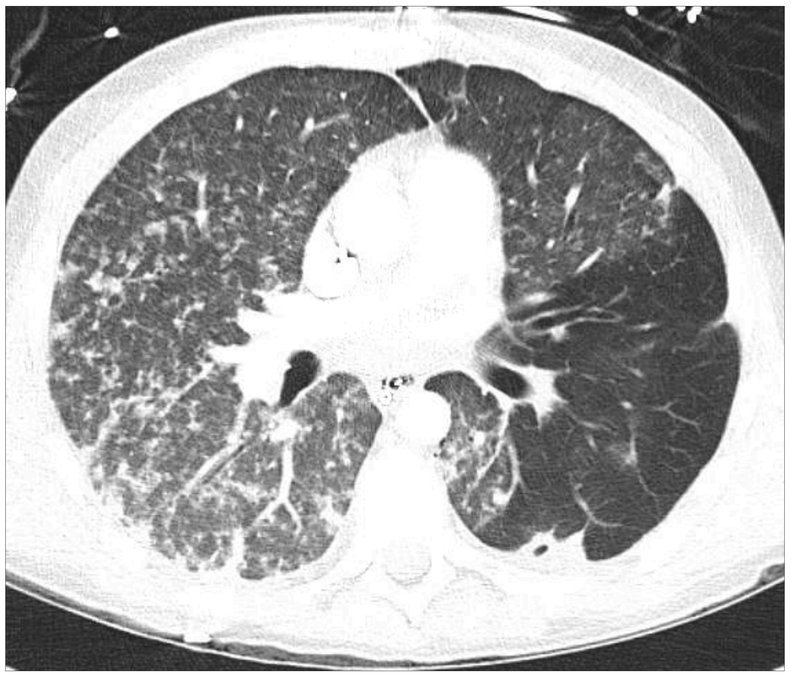

Figure II: Sagittal view of CT Chest Angiogram with IV contrast demonstrating pulmonary talcosis, again sparing the portion of the left lung lacking blood supply from a previous pulmonary embolism.

Answers

1. This triad is concerning for intravenous abuse of oral narcotics leading to diffuse lung disease.

2. The ultimate diagnosis in this patient is talc pneumoconiosis, a granulomatous reaction of the lung parenchyma in response to either inhaled or intravenous talc. Talc is a commonly used bulking agent in oral medications.

3. Interestingly, the large area of infarction from this patient's previous pulmonary embolism proves that the route of administration is intravenous, not inhalational, as the area of lung parenchyma lacking blood flow is spared from otherwise widespread disease.

Discussion/Pearls

- As increasing efforts are made to decrease rates of drug abuse in the United States, patients who suffer from addiction are finding novel ways to abuse these substances, which can have devastating effects.

- Intravenous injection of oral narcotics can lead to significant lung injury due to talc, the bulking agent used in most oral narcotics. These patients can present anywhere on the spectrum from mild dyspnea to fulminant respiratory failure.

- Patients with a history of chronic pulmonary talcosis are at high risk of developing a spontaneous pneumothorax due to significant damage to the lung parenchyma.

Case Conclusion

Injection of oral narcotics intravenously is a very dangerous way to abuse drugs, as talc can become lodged in the small capillary beds of the lungs. This can lead to extensive damage to the lung parenchyma, as is evidenced by these images. While it is often very difficult to determine inhalational vs intravenous exposure, in this particular patient we can definitively say he injected the oral narcotics due to relative sparing of the portion of the lung that lacks blood flow.

This patient had an uneventful inpatient stay and was discharged after three days. One month later, he was returned to the emergency department with a spontaneous tension pneumothorax and was readmitted to the ICU .

REFERENCES

1. Arnett WE, Russo JV, Roberts WC. *Intravenous injection of talc-containing drugs intended for oral use: a cause of pulmonary granulomatosis and pulmonary hypertension.* Am J Med 1976 May 10; 60(5):711-8
2. Roberts WC. *Pulmonary talc granulomas, pulmonary fibrosis, and pulmonary hypertension resulting from intravenous injection of talc-containing drugs intended for oral use.* Baylor UMC 2002 Jul 15 (3)260-261
3. Siddiqui M, Saleem S, Badireddi S. *Pulmonary talcosis with intravenous drug abuse.* J Resp Care. 2013 October 17; 50 (10) e126-e128
4. Hedden, Sarra, Kennett, Joel, et al. *Behavioral Health Trends in the United states: Results from the 2014 National Survey on Drug Use and Health.* US Department of Health and Human Services, 2015, www.samhsa.gov/data/sites/default/files/NSDUH-FRR1-2014
5. Dekel Y, Rath-Wolfson L, Rudniki C, Koren R. *Talc Inhalation is a Life-threatening Condition.* Patholo Oncol Res 2004; 10(4) 231-233
6. Ward S, Heyneman LE, Reittner P, et al. *Talcosis Associated with IV Abuse of Oral Medications: CT Findings.* Am J Roentgenol 2000; 174(3): 789-793
7. Marchiori E, Souza AS, Muller NL. *Inhalational Pulmonary Talcosis: High-Resolution CT Findings in 3 Patients.* J Thoracic Imaging 2004: 19(1): 41-44